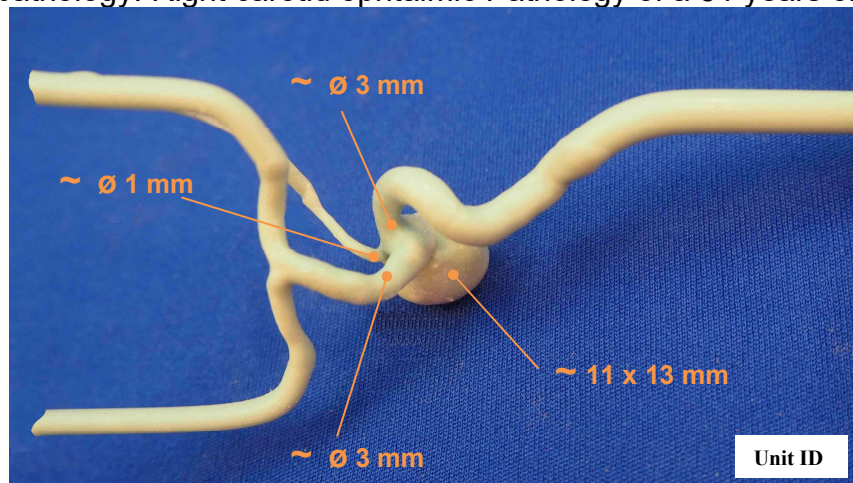
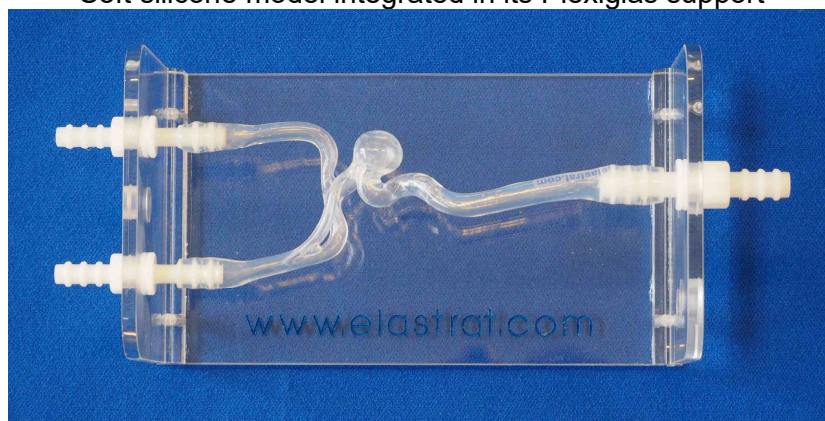



Head model “Specific patient” reference 118

Place of pathology: Right carotid ophtalmic Pathology of a 51 years old person



Soft silicone model integrated in its Plexiglas support



Head model shown with a 1 liter plastic tank and a continuous flow pump

