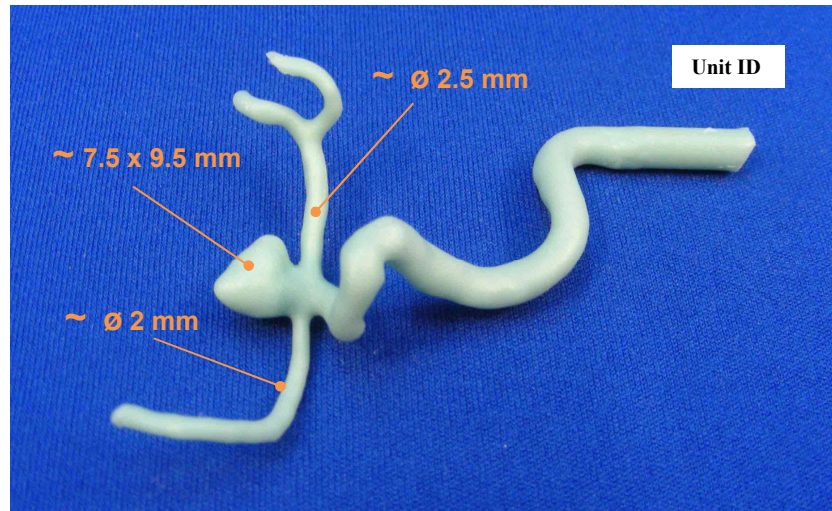
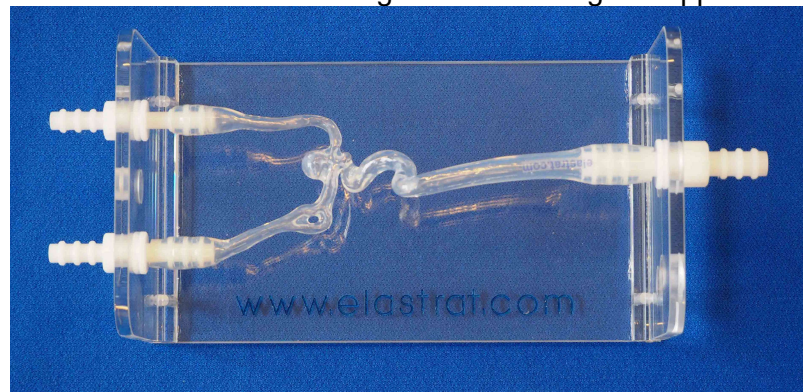



Head model “Specific patient” reference 123

Place of pathology: Left carotid ophtalmic Pathology of a 76 years old person



Soft silicone model integrated in a Plexiglas support



Head model shown with a 1 liter plastic tank and a continuous flow pump

