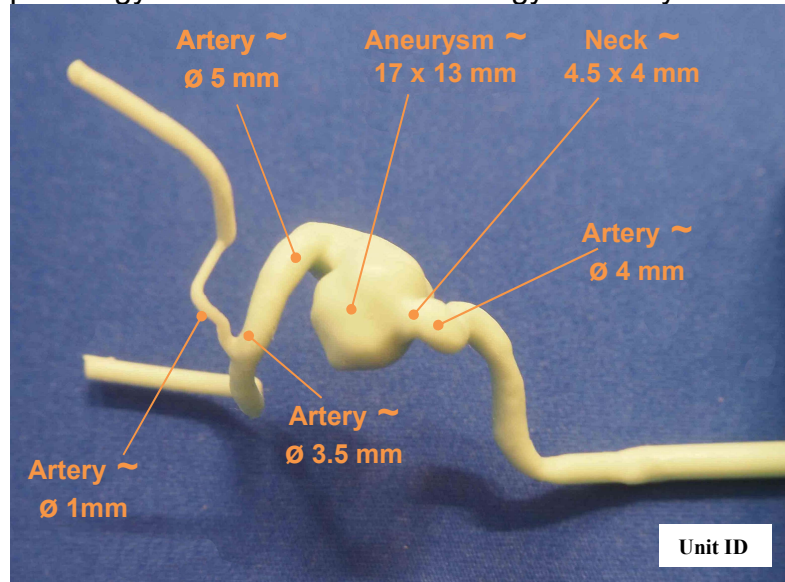





Head model “Specific patient” reference 116

Place of pathology: LICA cavernous Pathology of a 65 years old person



Soft silicone model integrated in its Plexiglas support



Head model shown with a plastic tank of 2 liter and a continuous flow aquarium pump

