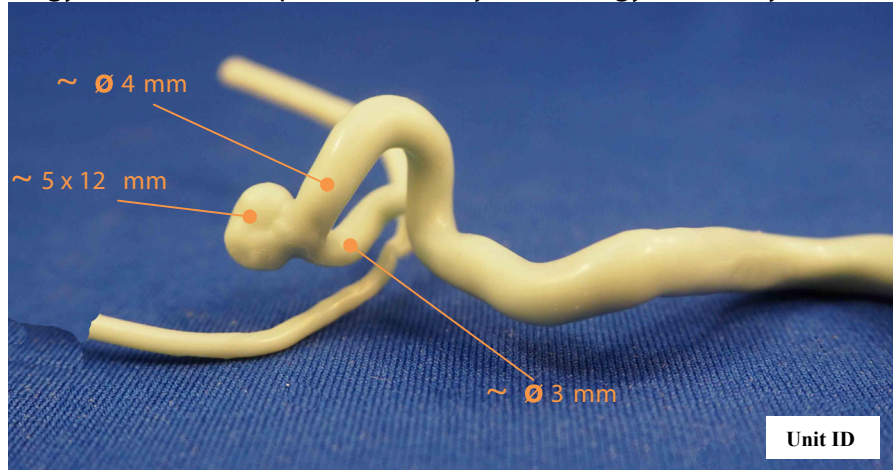
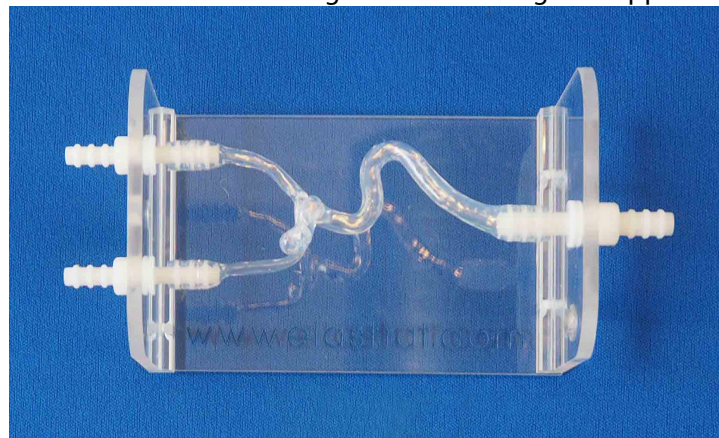



Head Model Specific Patient reference : 111

Place of pathology: Left carotid ophtalmic artery. Pathology of a 76 years old person



Soft silicone model integrated in its Plexiglass support



Head model shown with a 2 Lt plastic tank and a continuous flow aquarium pump

