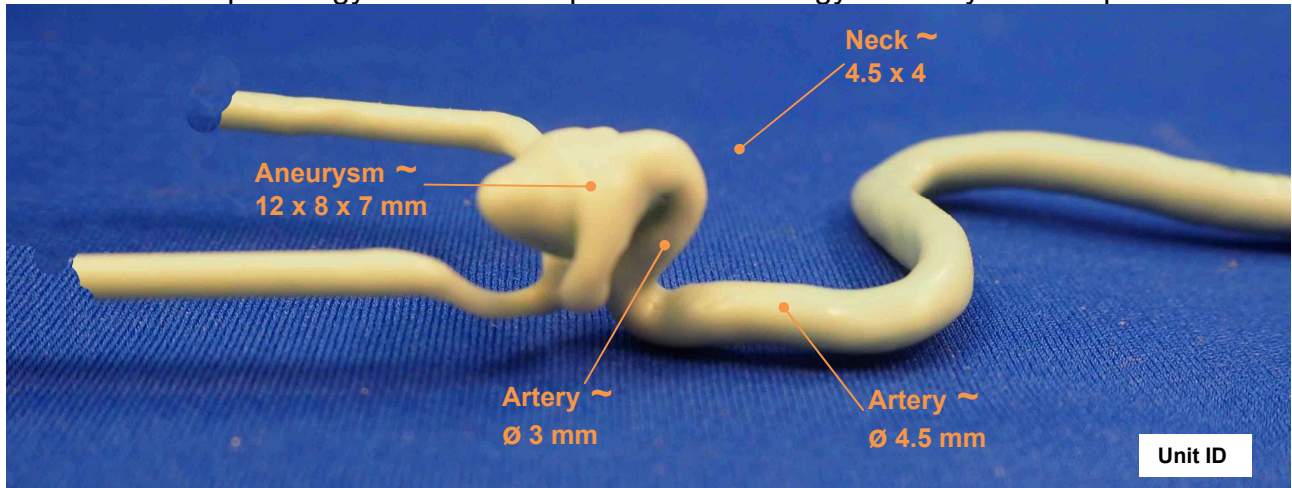


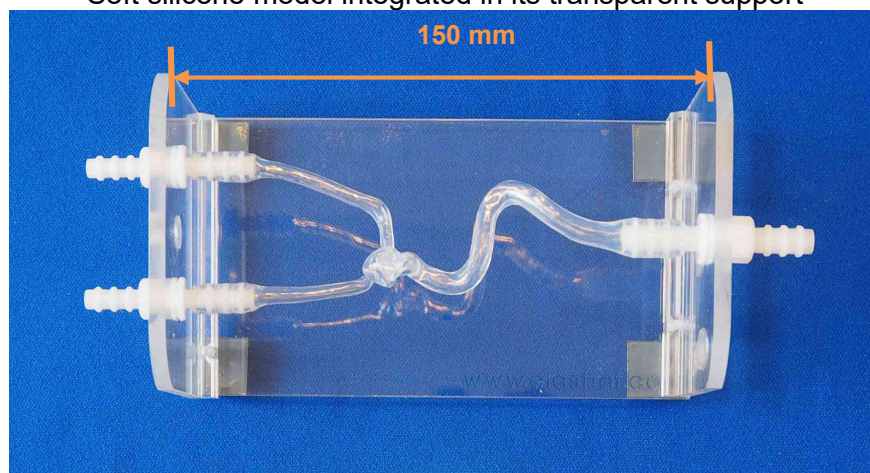


Head model “Specific patient” reference 110

Place of pathology: Left carotid ophthalmic. Pathology of a 37 years old person



Soft silicone model integrated in its transparent support



Head model shown with a 1 liter plastic tank and a continuous flow pump

