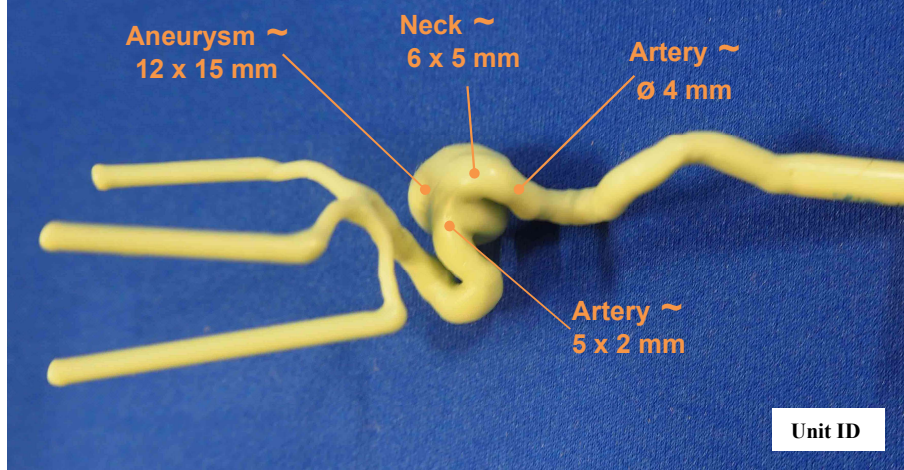


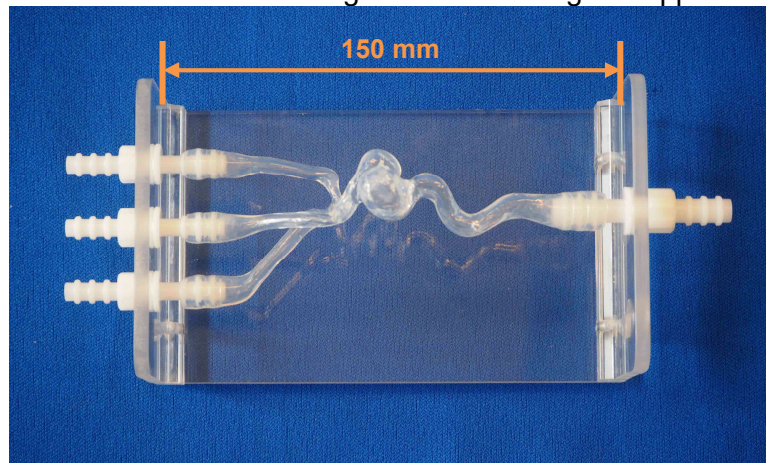


## Head model “Specific patient” reference 106-1

Place of pathology: LICA cavernous Pathology of a 71-year-old person



Soft silicon model integrated in its Plexiglas support



Head model Ref 106-1+ shown with a plastic tank and a continuous flow pump (red alimentary dye)

